

See discussions, stats, and author profiles for this publication at: <https://www.researchgate.net/publication/324704012>

# Biochemical changes in diabetic retinopathy triggered by hyperglycaemia: A review

Article · April 2018

DOI: 10.4102/aveh.v77i1.439

---

CITATIONS

0

READS

212

1 author:



Solani David Mathebula

University of Limpopo

36 PUBLICATIONS 68 CITATIONS

SEE PROFILE


Some of the authors of this publication are also working on these related projects:



Subjective and objective comparison of amplitude of accommodation determined subjectively and objectively in South African university students [View project](#)

# Biochemical changes in diabetic retinopathy triggered by hyperglycaemia: A review



**Author:**  
Solani D. Mathebula<sup>1</sup> 

**Affiliation:**  
<sup>1</sup>Department of Optometry,  
University of Limpopo,  
South Africa

**Corresponding author:**  
Solani Mathebula,  
solani.mathebula@ul.ac.za

**Dates:**  
Received: 22 Nov. 2017  
Accepted: 05 Feb. 2018  
Published: 23 Apr. 2018

**How to cite this article:**  
Mathebula SD. Biochemical changes in diabetic retinopathy triggered by hyperglycaemia: A review. Afr Vision Eye Health. 2018;77(1), a439. <https://doi.org/10.4102/aveh.v77i1.439>

**Copyright:**  
© 2018. The Author(s).  
Licensee: AOSIS. This work is licensed under the Creative Commons Attribution License.

**Background:** Diabetes mellitus (DM) is now a global health problem which will lead to increasing incidence of macrovascular and microvascular complications that contribute to morbidity, mortality and premature deaths. Diabetic retinopathy (DR) is a serious complication of DM, and its prevalence is increasing worldwide. Diabetes mellitus is one of the fastest growing causes of visual impairment and blindness in the working-age population.

**Aim:** The aim of this paper was to introduce the multiple interconnecting biochemical pathways that have been proposed and tested as key contributors in how the diabetic eye loses vision.

**Method:** An extensive literature search was performed using the Medline database from 1970 to present. The search subjects included diabetes and eye, diabetic retinopathy and diabetic complications in the eye. The search was limited to the literature pertaining to humans and to English language. Preference was given to recent published papers.

**Results:** Results were limited to human participants with publications in English. References of all included papers were also scrutinized to identify additional studies. Studies were selected for inclusion in the review if they met the following criteria: subjects with diabetes, pathophysiology of diabetic retinopathy.

**Conclusion:** Although the biochemical pathways involved in DR have been researched, to date the exact mechanism involved in the onset and progression of the disease is uncertain, which makes therapeutic interventions challenging. The aim of this review is to discuss the possible biochemical pathways and clinical and anatomical changes that occur during the onset and progression of DR that link hyperglycaemia with retinal tissue damage. An understanding of the biochemical and molecular changes may lead to health care practitioners advising patients with DR on events that lead to possible complications of the diseases.

## Introduction

Diabetes mellitus (DM) is a group of chronic diseases marked by high levels of blood glucose resulting from defects in insulin production, insulin use or both.<sup>1,2,3,4,5</sup> The inability of the body to use glucose resulting from the deficiency of insulin leads to constant hyperglycaemia which results in chronic complications, dysfunction and failure of different organs, especially the eyes, kidneys, nerves, heart and blood vessels.<sup>1,2,3,4,5</sup> The prevalence of DM has increased exponentially reaching epidemic proportions throughout the world owing to changing lifestyle. The public health goal is to reduce morbidity and mortality and improve quality of life of diabetic patients. Diabetes mellitus is a chronic disease that is commonly classified based on aetiology, into four main groups, namely, Type 1, Type 2, gestational and other types of DM.<sup>1,2,3,4,5</sup>

Type 1 DM, also known as insulin-dependent or juvenile-onset diabetes, is most commonly an autoimmune process owing to pancreatic islet beta-cell destruction mediated by activated T lymphocytes, resulting in absolute or near-total insulin deficiency.<sup>1,2,3,4,5</sup> This type of diabetes includes approximately 5% – 10% of all patients with DM. These patients have a tendency of ketoacidosis. However, some forms of Type 1 DM have no known aetiology but those patients have permanent insulinopenia and are prone to ketoacidosis with no evidence of autoimmunity.<sup>5</sup>

Type 2 DM or noninsulin-dependent diabetes affects about 80% – 90% of diabetic patients. This type of diabetes may occur in genetically susceptible individuals with impaired insulin secretion or insulin resistance and bad regulation of glucose production in the liver.<sup>1,2,3,4,5</sup> Type 2 DM involves mechanisms of insulin resistance, impaired insulin secretion and increased production of glucose, resulting in a relative insulin deficiency. Insulin resistance can be improved by weight loss.<sup>1,2,3,4,5</sup> These patients do not develop ketoacidosis but may suffer hyperglycaemic coma.<sup>5</sup>

### Read online:



Scan this QR code with your smart phone or mobile device to read online.

Gestational DM is any degree of glucose intolerance recognised during pregnancy<sup>6</sup> and is characterised by a certain degree of insulin resistance that could be because of a combination of maternal adiposity and desensitising effects of several substances produced by the placenta.<sup>6</sup> It results from glucose intolerance which develops during pregnancy and occurs in approximately 7% of all pregnancies. Most cases resolve with delivery.

The fourth type includes other causes that can lead to the development of DM, such as monogenic disorders, genetic syndrome (also known as maturity-onset DM of the young, characterised by the onset of hyperglycaemia before the age of 25 years and autosomal-dominant inheritance), diseases of the exocrine pancreas, endocrinopathies, drug-induced diabetes, infections or antibodies against insulin receptors.<sup>5</sup>

Diabetes mellitus is now recognised as a global pathology. This disease is exponentially increasing the incidence of macrovascular and microvascular anomalies that contribute to morbidity and mortality or premature deaths.<sup>7,8,9,10,11</sup> The macrovascular complications that affect the large vessels include cardiovascular, cerebrovascular and peripheral vascular diseases, while the microvascular complications affect the small vessels involving the eye, nerves and the renal system.<sup>7,8,9,10,11</sup> Diabetes mellitus selectively damages these three cell types because their glucose transport rate does not decline quickly as a result of hyperglycaemia, leading to high glucose inside the cell.<sup>12</sup> It seems what causes possible complications involve mechanisms going on inside the cell, rather than outside.

The intracellular hyperglycaemia causes diabetic disorders and other tissue damage by mechanisms involving repeated acute changes in cellular metabolism that are reversible when euglycaemia is restored and/or when another mechanism which involves cumulative changes in long-lived macromolecules persist despite restoration of euglycaemia.<sup>12</sup> These mechanisms are also influenced by genetic determinants of individual susceptibility and by independent accelerating factors such as hypertension and hyperlipidaemia. The other cell types are able to reduce the transport of glucose inside the cell and their internal glucose concentration stays the same or constant.<sup>10</sup>

Diabetic retinopathy (DR) is one of the common complications of diabetes in which the retina of the eye becomes progressively damaged, leading to vision impairment and blindness.<sup>7,8,9,10,11</sup> The retina, an extension of the brain representing the central nervous system, consists of three major cell types: neurons (photoreceptors, bipolar, horizontal, amacrine and ganglion cells), glial cells (Muller cells, astrocytes and microglia or macrophages) and vascular cells (endothelial cells and pericytes). Neurons and glial cells comprise about 95% of the retinal mass. The glial cells serve as support cells for neurons and blood cells (such as for nutrition and regulatory processes). Pericytes provide vascular stability and control endothelial proliferation, and also participate in basement membrane formation. Endothelial cells play a key role in the control of

vascular tone, homeostasis and immunological processes. There is a continual ongoing functional interaction between endothelial cells and pericytes, astrocytes, Muller cells and circulating blood cells.<sup>7,8,9</sup>

The retina has dual circulation: vascular and avascular.<sup>7,8,9</sup> The vascular circulation has blood vessels, while the avascular circulation receives nutrient supply from the choroidal circulation. The endothelial cell membranes are infused by tight junctions responsible for the inner blood–retinal barrier.<sup>9</sup> The outer blood–retinal barrier is formed by the retinal pigment epithelium. The inner blood–retinal barrier provides tight seals between cells and controls the flux of fluid, proteins and ions, while the outer blood–retinal barrier regulates fluids and molecular movement, and prevents macromolecules and other potentially harmful agents from leaking into the retina. The outer retinal layers are avascular and are supplied by diffusion from the choroidal circulation, while the retinal blood vessels provide nourishment to the inner retinal layers and carry away products from them.<sup>7,8,9</sup>

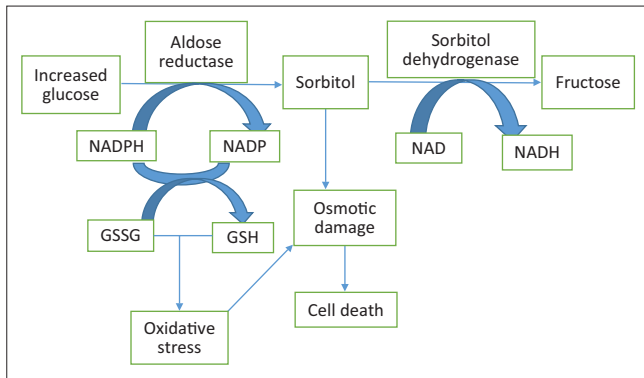
Diabetic retinopathy is a multifactorial progressive disease of the retina where the pathogenesis of the disease is extremely complex involving many different cells, molecules and factors. The problem is further complicated by the fact that DR may be asymptomatic until a severe stage is reached. Despite the current scientific developments, the mechanisms through which hyperglycaemia leads to retinal pathology remain inconclusive. It is crucial to understand the biochemical and molecular mechanisms to clarify the diseases pathogenesis. Understanding of the biochemical and molecular changes in the diabetic retina may lead to new and effective therapies towards prevention and amelioration of DR. Hence, it is the purpose of this review to present recent advances in understanding the biochemical and molecular mechanisms of DR. Understanding of the microvascular damage may drive the development of new drugs for the treatment of DR because of hyperglycaemia.

## Biochemical pathogenesis

Mechanisms that may explain toxicity of glucose in diabetes include polyol pathway, formation of advanced glycation end products (AGEs), activation of protein kinase C (PKC), oxidative stress, formation of reactive oxygen species (ROS) and increased hexosamine pathway flux.

### Polyol or sorbitol pathway

In cellular glucose metabolism, a small fraction of glucose is normally metabolised through the polyol pathway.<sup>13,14,15,16,17,18,19</sup> In diabetes, there is an increase in the flux of glucose, and the excess glucose is metabolised in this pathway. The polyol pathway is controlled by two enzymes. Aldose reductase, the first enzyme, reduces glucose into sorbitol using nicotinamide adenine dinucleotide phosphate (NADNP) as a cofactor. Sorbitol is then oxidised or converted to fructose by sorbitol dehydrogenase, the second enzyme, with nicotinamide adenine dinucleotide (NAD) as a cofactor (see Figure 1).



NADPH, Nicotinamide adenine dinucleotide phosphate (reduced form); NADP, nicotinamide adenine dinucleotide phosphate; NAD, nicotinamide adenine dinucleotide; NADH, nicotinamide adenine dinucleotide (reduced form); GSSG, oxidized glutathione; GSH, reduced glutathione.

**FIGURE 1:** Polyol pathway. Hyperglycaemia increases flux through the polyol pathway which metabolises excess glucose. The consumption of nicotinamide adenine dinucleotide phosphate (NADPH) in the initial conversion of glucose to sorbitol results in less NADPH availability for the generation activity of glutathione reductase that maintains the adequate levels of reduced glutathione (GSH), which is an important cellular antioxidant. The depletion of GSH may lead to increased levels of reactive oxygen species, leading to oxidative stress.

Under euglycaemic conditions, sorbitol level is low, while during hyperglycaemia, sorbitol level increases owing to the flux of glucose through the polyol pathway.

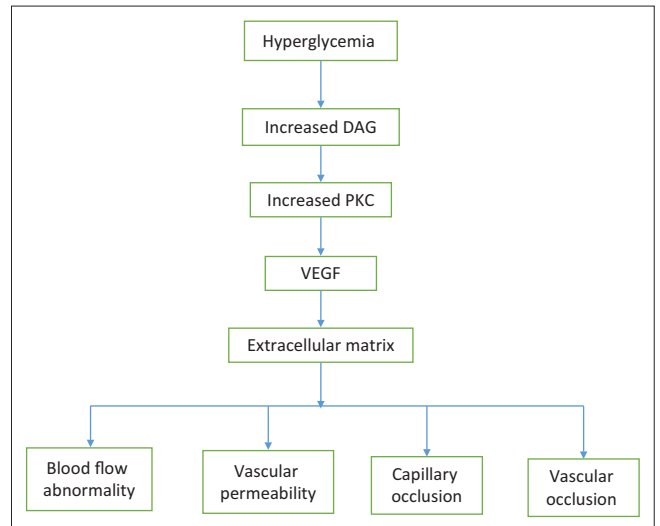
Since sorbitol is impermeable and cannot easily diffuse through cell or plasma membranes, and there is a slow metabolism of sorbitol to fructose, it accumulates within the retinal cells and causes osmotic damage to the retinal vascular cells, leading to DR.

### Increased intracellular formation of advanced glycation end products

The formation and accumulation of AGEs may contribute to DR.<sup>20,21</sup> Advanced glycation end products are a heterogeneous group of compounds formed as a result of a cascade of reactions starting with the non-enzymatic reaction of reducing sugars with free amino group of proteins, lipids and nuclei acids. Advanced glycation end products form at a constant but slow rate in the normal body, but their formation is markedly accelerated in diabetics because of the increased availability of glucose. Advanced glycation end products found in retinal vessels of diabetic patients are important pathogenic mediators of most diabetic complications. The interaction of AGEs with their receptors (RAGE) has been implicated in the development of DR.<sup>21</sup>

### Protein kinase C activation

In diabetes, hyperglycaemia induces elevated levels of diacylglycerol (DAG) that results in increased activation of PKC. Activation of PKC results in several pathways which in turn influence changes in endothelial permeability, retinal haemodynamics, expression of vascular endothelial growth factor (VEGF) in the retinal tissue as well as increased activation and adhesion of leukocytes (leukostasis), apoptosis, cytokine activation, basement membrane thickening, extracellular matrix expansion and abnormal angiogenesis.<sup>22,23,24</sup>



VEGF, vascular endothelial growth factor; DAG, diacylglycerol; PKC, protein kinase C.

**FIGURE 2:** The protein kinase C pathway. Chronic hyperglycaemia increases quantity of diacylglycerol (DAG) which leads to activation of protein kinase C (PKC). The PKC activation leads to increased vascular permeability and upregulation of vascular endothelial growth factors in the retinal structure. This may lead to increased activation of leukostasis and significant changes in extracellular matrix protein synthesis. Eventually, DAG and PKC pathways adversely affect inflammation, neovascularisation and retinal haemodynamics which lead to progression of diabetic retinopathy.

Diacylglycerol and PKC pathways adversely affect inflammation, neovascularisation and retinal haemodynamics which increase the progression of DR (see Figure 2).

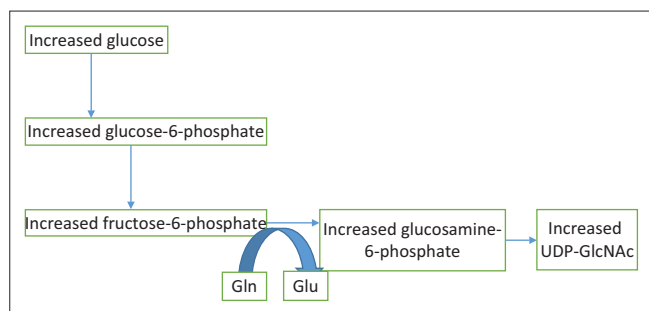
### Hexosamine pathway

The hexosamine pathway is activated when there is an excess of intracellular glucose that cannot be drained by glycolysis. When glucose is high inside the cell, most of it is converted to glucose-6-phosphate, which is then converted to fructose-6-phosphate.<sup>25</sup> Under euglycaemia, a small fraction of glucose is metabolised through the hexosamine pathway, while in hyperglycaemia, fructose-6-phosphate is converted to N-acetylglucosamine-6-phosphate by the enzyme glutamine fructose-6-phosphate amidotransferase (GFAT). The flux of glucose in this pathway leads to the rapid metabolism of glucosamine-6-phosphate, leading to the formation of uridine diphosphate N-acetylglucosamine (UDP-GlcNAc) which seems to be responsible for the alterations on protein function and gene expression that can reduce cell protection and in the end induce cell apoptosis on retinal neurons and endothelial cells (see Figure 3).

### Oxidative stress

Oxidative stress is a serious condition that may result in microvascular complications<sup>26,27,28,29,30</sup> and is an imbalance between the production of ROS or oxygen radicals and the ability of cells to remove or neutralise the ROS using antioxidants. Oxidative stress causes damage of cellular components and contributes to the pathogenesis of many diseases such as DR (see Figure 1).

In addition, PKC activation, hexosamine, polyol pathway and formation of AGEs can contribute to oxidative stress by



Gln, glutamate; Glu, cysteine.

**FIGURE 3:** The hexosamine pathway. The flux of fructose-6-phosphate into the hexosamine pathway is increased in diabetes. Activation of hexosamine is implicated in apoptosis of retinal capillary cells in diabetes. Glutamate (Gln) and cysteine (Glu) are the cofactors for synthesis of glycosyl side chains for proteins and lipids.

reducing the activities or levels of antioxidant enzymes. Nicotinamide adenine dinucleotide phosphate (NADPH) is an essential cofactor for regenerating antioxidant, reduced glutathione. Reducing the amount of reduced glutathione in turn increases susceptibility to intracellular oxidative stress. Oxidation of sorbitol by NAD increases the NADH, which in turn increases the concentration of triose phosphate.<sup>10,11</sup> Increased triose phosphate concentrations could increase formation of DAG, thus activating PKC. The retina and its vasculature are more susceptible to oxidative stress as it consumes more oxygen than the cerebral cortex and cardiac muscle. Reactive oxygen species plays a crucial role in mediating the inflammatory response.

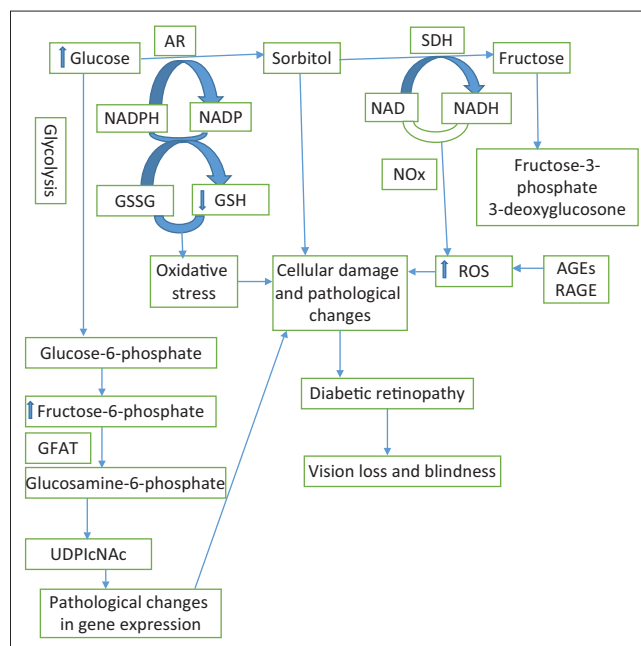
## Inflammation

Inflammation is a prominent part of the pathogenesis of DR. While hyperglycaemia, oxidative stress and AGEs formation all contribute to inflammation, the inflammatory response itself propagates these pathways further through cytokines, adhesion molecules and VEGF signalling.<sup>31,32,33</sup> In the retinal vasculature, the inflammatory response results in the formation of new weak vessels and their increased permeability owing to VEGF which in turn leads to haemorrhages in the retina and leukostasis. Leukostasis leads to capillary occlusion and non-perfusion.<sup>24</sup>

Vascular endothelial growth factor promotes angiogenesis (causes breakdown of the blood–retinal barrier, stimulation of endothelial cell growth and neovascularisation) and increases vascular permeability in the ischemic retina. Inflammation is the response of the body to pathogenesis and it is a prerequisite for tissue regeneration. However, how inflammation is generated in DR in the absence of pathogenesis is still unclear.

## Haemodynamic changes

It is believed that people with DM have a high incidence of hypertension, which is suggested as a potential mechanism in the onset and progression of DR.<sup>34,35,36,37,38</sup> The high blood pressure and increased retinal blood flow can lead to endothelial dysfunction by mechanical stretch and sheer



AR, aldose reductase; SDH, sorbitol dehydrogenase; NADPH, nicotinamide adenine dinucleotide phosphate (reduced form); NADP, nicotinamide adenine dinucleotide phosphate; GSSG, oxidized glutathione; GSH, reduced glutathione; NAD, nicotinamide adenine dinucleotide; NADH, nicotinamide adenine dinucleotide (reduced form); NOx, nitric oxide; ROS, reactive oxygen species; AGE, advanced glycation end-products; RAGE, receptor for advanced glycation end-products; GFAT, glutamine:fructose-6-phosphate amidotransferase; UDP-GlcNAc, uridine diphosphate N-acetylglucosamine.

**FIGURE 4:** Unified biochemical mechanisms of diabetic complication in the retina. The polyol pathway is started by the conversion of glucose to sorbitol, and the further reduction of sorbitol into fructose by aldose reductase and sorbitol dehydrogenase enzymes, respectively. All of these pathways lead to increased oxidative stress, inflammation and vascular dysfunction. Oxidative stress and inflammation result in upregulation of growth factors which contribute to breakdown of the blood–retinal barrier and development of diabetic macular oedema.

stress, and secondly, the loss of autoregulation is implicated in the pathogenesis of DR.

Renin-angiotensin-aldosterone system (RAAS) is the endocrine system that regulates vascular blood pressure, electrolytes and fluid balance.<sup>37,38</sup> It has been implicated in the onset and progression of DR. Although the exact mechanism by which RAAS contributes to DR is not clear, it has been suggested that angiotensin II is involved in PKC activation and VEGF signalling.

## A single unified biochemical mechanism of diabetic retinopathy

It seems there is no apparent common element linking the biochemical mechanisms to each other in the pathogenic onset and progression of DR (see Figure 4). However, the complexities of the pathways involved in different stages of the disease remain a challenging issue for drug delivery.

## Molecular mechanism

Diabetic retinopathy develops in stages and various pathophysiological processes can be identified during the course of the diseases.<sup>39,40,41,42,43,44,45,46</sup> Sustained hyperglycaemia leads to a breakdown of the blood–retinal barrier, wherein the tight junctions of the endothelial cells in the blood–retinal barrier become loose, enabling entry of macromolecules and



leading to the capillary thickness and rigidity of the blood vessels. This dysfunction autoregulation results in diminished blood flow.

Then, there is loss of pericytes, which cannot be seen clinically but can be detected only by histological examination.<sup>40,41</sup> Pericyte loss leads to changes in endothelial cells. Dilation of capillary wall appears in areas where pericytes have been lost. Thus, capillaries become leaky and allow fluid, macromolecules, and even blood to seep out into the retina. The dilatation of capillary wall is called microaneurysm, which is the earliest clinically observable lesion of DR and is clinically identified by ophthalmoscopy as small red dots (haemorrhage) and yellow deposits (hard exudates). Hard exudates are the result of increased thickness of basement membrane.

The damage caused to pericytes leads to a change in retinal haemodynamics, including abnormal autoregulation of the retinal blood flow. This is followed by loss of retinal capillary endothelial cells. Thus, the endothelial cells and pericytes of the retinal microvascular suffer apoptosis. Then, there is an increased leukostasis,<sup>45</sup> which seems to play an important role in the pathogenesis of the diseases.

The basement membrane thickening, disruption of the blood-retinal barrier and loss of pericytes and endothelial cells can all lead to local tissue ischemia. Other associated observable clinical findings are white patches called cotton wool spots, which represent localised arrest of the axoplasmic transport of retinal nerve fibres owing to retinal nerve fibre infarction.<sup>1,2,43,44</sup>

Diabetic retinopathy is clinically classified based on the location, extent and degree of various clinically significant features such as microaneurysms, intraretinal haemorrhages, venous abnormalities and neovascularisation into non-proliferative diabetic retinopathy (NPDR) and proliferative diabetic retinopathy (PDR) stages.<sup>1,2,43</sup> The NPDR is further classified as mild, moderate and severe. The mild NPDR is characterised by few microaneurysms. The moderate form has less than 20 microaneurysms. Hard yellow exudates, cotton wool spots and venous beading are also present in one quadrant.<sup>43</sup> The severe form of NPDR has microaneurysms in all four quadrants, venous beading in two or more quadrants and intraretinal microvascular abnormalities (IRMA) in one or more quadrants. The changes mentioned above are the major complications of NPDR. Then, NPDR proceeds to PDR. When perfusion is sufficiently low, hypoxia stimulates the development of neovascularisation (new vessels from the existing one). These newly-formed blood vessels (neovessels) erupt through the surface of the retina and proliferate into the vitreous cavity.<sup>43</sup> However, these vessels are fragile and tend to break, causing vitreous haemorrhaging and subsequent loss of vision and may scar the vitreous body, leading to retinal detachment and ultimately to blindness. Neovascularisation is also called angiogenesis, which is a consequence of an imbalance of the growth factors that contribute to the development of other retinal diseases.

## Current and new therapeutics

Several studies have reported that hyperglycaemia, hypertension and dislipidaemia are the major risk factors for DR.<sup>44,45</sup> Tight control of blood glucose, blood pressure and lipid lowering therapy are the most important management strategies to reduce the onset, incidence and progression of DR. The use of anti-hypertensive drugs showed the ability to reduce the progression of the disease.

Surgical management with laser surgery and vitrectomy provides an effective means of preventing and reducing vision loss.<sup>44,45</sup> Even though the laser treatment does not improve vision, it treats leaking blood vessels directly by sealing the area of leakage or by eliminating abnormal newly-formed blood vessels.<sup>45</sup> All of these treatments are focused on end-stage disease and carry significant sight-threatening side effects. Also, they do not address the early and potentially reversible failures of retinal perfusion. Development of new therapies capable of preventing or slowing the onset and progression of DR remains a priority. Several pharmaceutical therapies have been proposed but none have entered clinical use for early-stage DR.<sup>29</sup> These include corticosteroids, anti-angiogenic factors, protein C kinase inhibitors, growth hormone inhibitors, AGEs products inhibitors, antioxidants, anti-inflammatory drugs, anti-VEGF agents and the use of a nanoparticles-based approach.

## Challenges

The duration of diabetes, increased level of blood pressure and lipid level, plus the level of metabolic control are the risk factors for DR, but they do not explain the variability that characterises the onset and rate of progression of DR in different diabetic individuals. There are individual variations in the presentation and the course of DR. Not all patients with poor metabolic control develop stages of DR. There are many diabetic patients who, after many years with diabetes, never develop sight-threatening retinal changes and maintain good visual acuity. However, there are also other diabetic patients who, after only a few years of diabetes, show signs of DR that progress rapidly and may not even respond to available treatments.

Patients under good metabolic control may develop vision-threatening DR complications before other patients with poor metabolic control. Diabetes is a metabolic disease with strong genetic, lifestyle and environmental aetiology. Presence or absence of genetic factors may play a key role in determining specific pathways of vascular diseases, and different progression patterns of DR.

## Conclusion

Vision is the most indispensable means of communication and its loss is catastrophic. Since there is no cure for DR, the management should be a combination of both systematic and ocular aspects of the disease, and this should include the management of hyperglycaemia. These management

strategies could perhaps delay and attenuate some of the major symptoms, avoiding early blindness. Controlling and maintaining the optimal glycaemic level alone might not be enough to prevent DR in some diabetic patients.

Diabetic retinopathy is complex and multifactorial involving complex interplay between biochemical and metabolic disorders occurring in almost all cells in the retina. Despite the uncertain biochemical and biological mechanisms, the multifactorial nature of the diseases is evident; however, its treatment remains a clinical challenge. The possible biochemical pathways have been discussed. Precise molecular studies are required towards understanding the neovascular damage in early DR. Therefore, understanding the biochemical changes and molecular events under diabetic conditions are essential to develop novel therapeutic tools for the prevention and amelioration of DR.

## Acknowledgements

This article is based on support from the South African Medical Research Council (SAMRC) under SAMRC research strengthening and capacity building at selected universities. I would like to thank the referees for their comments.

## Competing interests

The author declares that he has no financial or personal relationships which may have inappropriately influenced him in writing this article.

## References

- Wild S, Reglic G, Green A, Sicree R, King H. Global prevalence of diabetes. *Diabetes Care*. 2004;27(5):1047–1053. <https://doi.org/10.2337/diacare.27.5.1047>
- Shaw J, Sicree R, Zimmet P. Global estimates of the prevalence of diabetes for 2010 and 2030. *Diabetes Res Clin Pract*. 2010;87(1):4–14. <https://doi.org/10.1016/j.diabres.2009.10.007>
- American Diabetes Association. Diagnosis and classification of diabetes mellitus. *Diabetes Care*. 2012;35(Suppl):S64–S71. <https://doi.org/10.2337/dc12-s064>
- Pickett KA. Microvascular complications of diabetes: What is relevant for practice? *J Nurse Practitioners*. 2016;12(10):683–689. <https://doi.org/10.1016/j.nurpra.2016.08.012>
- Conget I. Diagnosis, classification and pathogenesis of diabetes mellitus. *Rev Esp Cardiol*. 2002;55(5):528–535. [https://doi.org/10.1016/S0300-8932\(02\)76646-3](https://doi.org/10.1016/S0300-8932(02)76646-3)
- Vamberque A, Fajardy I. Consequences of gestational and pregestational diabetes on placental function and birth weight. *World J Diabetes*. 2011;2(11):196–203. <https://doi.org/10.4239/wjdv2.i11.196>
- Demuth K, Myara I, Moatti N. Biology of the endothelial cell and atherogenesis. *Ann Biol Clin*. 1995;53(4):171–191.
- Ejaz S, Chekarova I, Ejaz A, Sohail A, Lim CW. Importance of pericytes and mechanisms of pericyte loss during diabetic retinopathy. *Diabetes Obes Metab*. 2008;10(1):53–63.
- Gardner TW, Antonetti DA, Barber AJ, Lieth E, Tarbell JA. The molecular structure and function of the inner blood-retinal barrier: Penn State Research Group. *Doc Ophthalmol*. 1997;97(3–4):229–237.
- Brownlee M. The pathobiology of diabetic complications. *Diabetes*. 2005;54(6):1615–1625. <https://doi.org/10.2337/diabetes.54.6.1615>
- Forbes JM, Cooper ME. Mechanisms of diabetic complications. *Physiol Rev*. 2013;93(1):137–188. <https://doi.org/10.1152/physrev.00045.2011>
- Kaiser N, Sasson S, Feener EP, et al. Differential regulation of glucose transport and transporters by glucose in vascular endothelial and smooth muscle cells. *Diabetes*. 1993;42(1):80–89. <https://doi.org/10.2337/diab.42.1.80>
- Nishikawa T, Edelstein D, Brownlee M. The missing link: A single unifying mechanism for diabetic complications. *Kidney Int*. 2000;58(Suppl):S26–S30. <https://doi.org/10.1046/j.1523-1755.2000.07705.x>
- Gabbay KH. The sorbitol pathway and the complications of diabetes. *N Engl J Med*. 1973;288(16):831–836. <https://doi.org/10.1056/NEJM197304192881609>
- Oates PJ. Polyol pathway and diabetic peripheral neuropathy. *Int Rev Neurobiol*. 2002;50:325–392.
- Gabbay KH. Hyperglycemia, polyol metabolism and complications of diabetes mellitus. *Ann Rev Med*. 1975;26:521–536.
- Kinoshita JH. A thirty year journey in the polyol pathway. *Exp Eye Res*. 1990;50(6):567–573. [https://doi.org/10.1016/0014-4835\(90\)90096-D](https://doi.org/10.1016/0014-4835(90)90096-D)
- Coucha M, Elshaer SL, Eldashaw WS, Mysona BA, El-Remessy AB. Molecular mechanisms of diabetic retinopathy: Potential therapeutic targets. *Middle East Afr J Ophthalmol*. 2015;22(2):135–144. <https://doi.org/10.4103/0974-9233.154386>
- Mathebula SD. Polyol pathway: A possible mechanism of diabetes complications in the eye. *Afr Vis Eye Health*. 2015;74(1):a13. <https://doi.org/10.4102/aveh.v74i1.13>
- Zong H, Ward M, Stitt AW. AGEs, RAGE and diabetic retinopathy. *Curr Diabetes Rep*. 2011;11(4):244–252. <https://doi.org/10.1007/s11892-011-0198-7>
- Chen M, Curtis TM, Stitt AW. Advanced glycation end products and diabetic retinopathy. *Curr Med Chem*. 2013;20(26):3234–3240. <https://doi.org/10.2174/09298673113209990025>
- Das Eucimen N, King GL. The role of protein kinase C activation and the vascular complications of diabetes. *Pharmacol Res*. 2007;55(6):498–510. <https://doi.org/10.1016/j.phrs.2007.04.016>
- Koya D, King GL. Protein kinase C activation and the development of diabetic complications. *Diabetes*. 1984;47(6):859–866. <https://doi.org/10.2337/diabetes.47.6.859>
- Chibber R, Ben-Mahmud BM, Chibber S, Kohner EM. Leukocytes in diabetic retinopathy. *Curr Diabetes Rev*. 2007;3(1):3–14. <https://doi.org/10.2174/15733990779802139>
- Schleicher ED, Weigert C. Role of the hexosamine biosynthesis pathway in diabetic nephropathy. *Kidney Int*. 2000;77(Suppl):S13–S18. <https://doi.org/10.1046/j.1523-1755.2000.07703.x>
- Kitada M, Zhang Z, Mima A, King GL. Molecular mechanisms of diabetic vascular complications. *J Diabetes Invest*. 2010;1(3):77–89. <https://doi.org/10.1111/j.2040-1124.2010.00018.x>
- Giacco F, Brownlee M. Oxidative stress and diabetic complications. *Circ Res*. 2010;107(9):1058–1070. <https://doi.org/10.1161/CIRCRESAHA.110.223545>
- Kowluru RA, Chan PS. Oxidative stress and diabetic retinopathy. *Exp Diabetes Res*. 2007;2007:43603. <https://doi.org/10.1155/2007/43603>
- Tarr JM, Kaul K, Chopra M, Kohner EM, Chibber R. Pathophysiology of diabetic retinopathy. *ISRN Ophthalmol*. 2013;2013:343560. <https://doi.org/10.1155/2013/343560>
- Madsen-Bouterse SA, Kowluru RA. Oxidative stress and diabetic retinopathy: Pathophysiological mechanisms and treatment perspectives. *Rev Endocr Metab Disord*. 2008;9(4):315–327. <https://doi.org/10.1007/s11154-008-9090-4>
- Wirostko B, Wong TY, Simo R. Vascular endothelial growth factor and diabetic complications. *Prog Retin Eye Res*. 2008;27(6):608–621. <https://doi.org/10.1016/j.preteyeres.2008.09.002>
- Sayin N, Kara N, Pekel G. Ocular complications of diabetes mellitus. *World J Diabetes*. 2016;6(1):92–108. <https://doi.org/10.4239/wjdv6.i1.92>
- Zhang W, Liu H, Al-Shabraway M, Caldwell RW, Caldwell RB. Inflammation and diabetic retinal microvascular complications. *J Cardiovasc Dis Res*. 2011;2(2):96–103. <https://doi.org/10.4103/0975-3583.83035>
- Simonson DC. Etiology and prevalence of hypertension in diabetic patients. *Diabetes Care*. 1988;11(10):821–827. <https://doi.org/10.2337/diacare.11.10.821>
- Mancia G. The association of hypertension and diabetes: Prevalence, cardiovascular risk and protection by blood pressure reduction. *Acta Diabetologica*. 2005;42(Suppl):S17–S25. <https://doi.org/10.1007/s00592-005-0177-z>
- Kohner EM. The retinal blood flow in diabetes. *Diabete et Metabolisme*. 1993;19(5):401–404.
- Wilkinson-Berka JL. Angiotensin and diabetic retinopathy. *Int J Biochem Cell Biol*. 2006;38(5–6):752–765. <https://doi.org/10.1016/j.biocel.2005.08.002>
- Giacchetti G, Sechi LA, Rilli S, Carey RM. The renin-angiotensin-aldosterone system, glucose metabolism and diabetes. *Trends Endocrinol Metab*. 2005;16(3):120–126. <https://doi.org/10.1016/j.tem.2005.02.003>
- Lieth E, Gardner TW, Barber AJ, Antonetti A. Retinal neurodegeneration: Early pathology in diabetes. *Clin Exp Ophthalmol*. 2000;28(1):3–8. <https://doi.org/10.1046/j.1442-9071.2000.00222.x>
- Cunha-Vas JG, Faria DE, Abreu JR, Campos AJ, Figo GM. Early breakdown of the blood-retinal barrier in diabetes. *Br J Ophthalmol*. 1975;59:649–656. <https://doi.org/10.1136/bjo.59.11.649>
- Cunha-Vas J. The blood-retinal barrier in retinal disease. *Eur Ophthalmic Rev*. 2009;3(2):105–108. <https://doi.org/10.17925/EOR.2009.03.02.105>
- Villarreal M, Ciudin A, Hernandez C. Neurodegeneration: An early event of diabetic retinopathy. *World J Diabetes*. 2010;1(2):57–64. <https://doi.org/10.4239/wjdv1.i2.57>

43. Ahsan A. Diabetic retinopathy-biomolecules and multiple pathophysiology. *Diab Met Syndr: Clin Res Rev.* 2015;9(1):51–54. <https://doi.org/10.1016/j.dsx.2014.09.011>
44. Heng LZ, Comyn O, Peto T, et al. Diabetic retinopathy: Pathogenesis, clinical grading, management and future developments. *Diabet Med.* 2013;30(6):640–650. <https://doi.org/10.1111/dme.12089>
45. Davidson JA, Ciulla TA, McGill JB, Kles KA, Anderson PW. How the diabetic eye loses vision. *Endocr.* 2007;32(1):107–116. <https://doi.org/10.1007/s12020-007-0040-9>
46. Cunha-Vas J, Ribeiro L, Lobo C. Phenotypes and biomarkers of diabetic retinopathy. *Prog Retin Eye Res.* 2014;41:90–111. <https://doi.org/10.1016/j.preteyeres.2014.03.003>